

awareness of MJD subtype IV and encourage the search for the mutation in patients presenting with atypical parkinsonism combined with features of peripheral neuropathy [16–18]. Obviously, a family history of neurologic disease would further support this; however, the absence of this feature, as was initially the case in our second patient, should not detract from the diagnostic consideration.

Part of this work was sponsored by the Alzheimer Association of Ontario, the Medical Research Council of Canada, and the Parkinson Foundation of Canada.

## References

- Sequeiros J, Coutinho P. Epidemiology and clinical aspects of Machado-Joseph disease. In: Harding AE, Deufel T, eds. *Advances in neurology*, vol 61. New York: Raven Press, 1993: 139–153.
- Takiyama Y, Ikemoto S, Tanaka Y, et al. A large Japanese family with Machado-Joseph disease: clinical and genetic studies. *Acta Neurol Scand* 1989;79:214–222.
- Rosenberg RN. Dominant ataxias. In: Kety SS, Rowland LP, Sidman RL, Matthysse SW, eds. *Genetics of neurological and psychiatric disorders*. New York: Raven Press, 1983:195–213.
- Kawaguchi Y, Okamoto T, Taniwaki M, et al. CAG expansions in a novel gene for Machado-Joseph disease at chromosome 14q32.1. *Nature Genet* 1994;8:221–228.
- Takiyama Y, Igarashi S, Rogaeva EA, et al. Evidence for intergenerational instability in the CAG repeat in the MJD1 gene and for conserved haplotypes at flanking markers amongst Japanese and Caucasian subjects with Machado-Joseph disease. *Hum Mol Genet* 1995;4:1137–1146.
- Lang AE, Fahn S. Assessment of Parkinson's disease. In: Munsat TL, ed. *Quantification of neurological deficit*. Stoneham: Butterworths, 1989:285–309.
- St George-Hyslop P, Haines P, Rogaev E. Genetic evidence for a novel familial Alzheimer disease gene on chromosome 14. *Nature Genet* 1992;2:330–334.
- Barbeau A, Roy M, Cunha L, et al. The natural history of Machado-Joseph disease. An analysis of 138 personally examined cases. *Can J Neurol Sci* 1984;11:510–525.
- Woods BT, Schaumburg HH. Nigro-spino-dentatal degeneration with nuclear ophthalmoplegia. A unique and partially treatable clinico-pathological entity. *J Neurol Sci* 1972;17:149–166.
- Romanul FCA, Fowler HL, Radvany J, et al. Azorean disease of the nervous system. *N Engl J Med* 1977;296:1505–1508.
- Rosenberg RN, Nyhan WL, Coutinho P, Bay C. Joseph's disease: an autosomal dominant neurological disease in the Portuguese of the United States and the Azores Islands. In: Kark RAP, Rosenberg RN, Schur LJ, eds. *Advances in neurology*, vol 21. New York: Raven Press, 1978:33–57.
- Fowler HL. Machado-Joseph-Azorean disease. A ten-year study. *Arch Neurol* 1984;41:921–925.
- Spinella GM, Sheridan PH. Research initiatives on Machado-Joseph disease: National Institute of Neurological Disorders and Stroke workshop summary. *Neurology* 1992;42:2048–2051.
- Rosenberg RN, Nyhan WL, Bay C, Shore P. Autosomal dominant striatonigral degeneration. *Neurology* 1976;26:703–714.
- Lang AE, Rogaeva EA, Tsuda T, et al. Homozygous inheritance of the Machado-Joseph disease gene. *Ann Neurol* 1994;36: 443–447.
- van der Wiel HL, Staal A. External ophthalmoplegia, juvenile parkinsonism and axonal polyneuropathy in two siblings. *Clin Neurol Neurosurg* 1981;83:247–252.
- Byrne E, Thomas PK, Zilkha KJ. Familial extrapyramidal disease with peripheral neuropathy. *J Neurol Neurosurg Psychiatry* 1982;45:372–374.
- Jaradeh S, Dyck PJ. Hereditary motor and sensory neuropathy with treatable extrapyramidal features. *Arch Neurol* 1992;49: 175–178.

## Reversible Dementia and Apparent Brain Atrophy During Valproate Therapy

Oscar Papazian, MD,\* Elizabeth Cañizales, MD,†  
Israel Alfonso, MD,\* Ricardo Archila, MD,†  
Michael Duchowny, MD,\* and Jean Aicardi, MD, FRCP\*

Two children developed severe cognitive and behavioral deterioration suggestive of a degenerative disease while being treated with sodium valproate for idiopathic, localization-related epilepsy with centrottemporal spikes. Magnetic resonance imaging revealed marked central and generalized cortical and cerebellar atrophy. In both patients, clinical symptoms and signs cleared in a few weeks following valproate withdrawal. The magnetic resonance imaging appearance improved within 3 months in 1 of the patients and normalized in both after 6 and 12 months. No metabolic changes were associated with the clinical or imaging abnormalities. Although the mechanism of this rare idiosyncratic complication of valproate therapy is unknown, we advocate discontinuing valproate therapy in all epileptic patients with neurological deterioration or brain atrophy of unknown etiology.

Papazian O, Cañizales E, Alfonso I, Archila R, Duchowny M, Aicardi J. Reversible dementia and apparent brain atrophy during valproate therapy. *Ann Neurol* 1995;38:687–691

A number of undesirable side effects of valproic acid or sodium valproate therapy in children have been reported [1]. The most severe reactions are acute liver dysfunction [2] and pancreatitis [3]. Minor adverse neurological side effects are more frequent but severe complications involving the central nervous system are rare [4–6].

From the \*Department of Neurology, Miami Children's Hospital, Miami, FL, and †Neuropediatric Unit, Hospital Miguel Perez Carreño, Caracas, Venezuela.

Received Apr 19, 1995, and in revised form Jun 21. Accepted for publication Jun 21, 1995.

Address correspondence to Dr Papazian, 3200 SW 60th Ct, #302, Miami, FL 33155.

We describe 2 children who showed reversible brain atrophy on neuroimaging studies associated with severe behavioral, cognitive, and neurological dysfunction while receiving sodium valproate for the treatment of seizures. Only one similar case has been reported previously [7].

## Case Histories

### Patient 1

A boy presented at age 5 years, 8 months with six partial seizures involving the left side of the body. The first two seizures were prolonged (>20 minutes) secondary generalized episodes that required hospitalization. Subsequent seizures were brief and involved the face without loss of consciousness. Electroencephalography (EEG) revealed normal background activity with a focus of sharp waves in the right central region consistent with the diagnosis of benign rolandic epilepsy (BRE). A cranial computed tomography (CT) scan appeared normal.

His psychomotor development was normal but he had attention deficit disorder with hyperactivity (ADDH). He was initially treated with phenytoin but was switched to carbamazepine and phenobarbital because of persistent seizures. Following his fourth seizure, at age 8 years, 2 months, he was started on sodium valproate monotherapy (divalproex sodium [Depakote]), 625 mg three times a day, producing blood levels of 91 to 106 mg/dl, and methylphenidate (Ritalin), 20 mg twice daily for his ADDH. This last medication was replaced by thioridazine (Mellaril), 25 mg twice daily, and benztropine mesylate (Cogentin), 2 mg/day, at age 9 years, 9 months.

Decreasing motor ability was first noted by his teacher at age 10 years, 6 months (22 and 9 months after starting sodium valproate and thioridazine and benztropine mesylate) and progressed over the following months. He subsequently became inactive, began to play with dolls like a small child, and spent much of the day alone, inactive or watching television. Speech also deteriorated with reduced output and garbled sounds. He developed an intention tremor of the hands and difficulty with balance. Examination corroborated these findings and revealed mild dysmetria and ataxia on tandem gait and marked obesity at age 10 years, 8 months. At age 11 years, 4 months his full-scale IQ (Wechsler Intelligence Scale for Children—III) dropped to 74 (verbal 73, performance 79) from a full-scale IQ of 96 (verbal 94, performance 101) obtained at the age of 7 years, 11 months. Subtests of similarities, arithmetic, and comprehension were most affected while visuospatial function was spared. Blood levels of valproate taken at 24-hour intervals were 110 and 119 mg/dl at the time of follow-up psychometric testing.

A progressive degenerative disorder was suspected but multiple laboratory examinations showed normal values of parameters, including leukocytes hexosaminidase and beta-galactosidase activities, blood transaminases, free and acyl carnitine, phytanic acid, very-long-chain fatty acid, and amino and organic acids in blood and urine. Ammonia levels taken at 24-hour intervals were mildly elevated (80 and 53 mg/dl). Magnetic resonance imaging (MRI) revealed a moderate generalized increase in ventricular size and dilatation of the cortical sulci and pericerebral spaces. The cerebellar hemi-

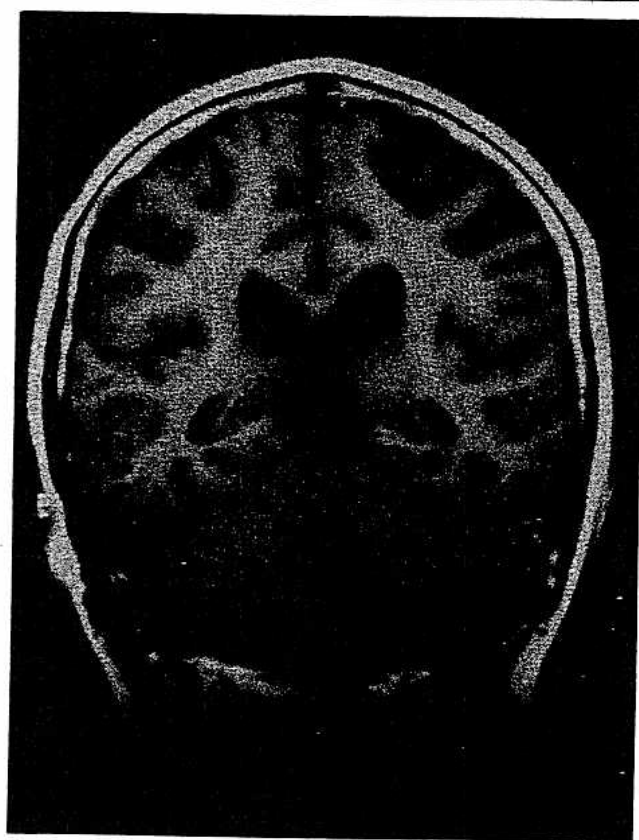
spheres were also markedly atrophic (Fig A). The EEG background remained normal and the left central focus was still present. Visual and somatosensory evoked potentials, electromyography (EMG), and conduction velocities were normal.

Sodium valproate, thioridazine, and benztropine mesylate were discontinued at age 11 years, 6 months. Felbamate (Felbatol), 600 mg three times a day, was started. Seven weeks later his behavior changed strikingly. He began to read, no longer played with puppets, and resumed his previous level of hyperactivity. Speech also returned to normal, gait and vertical stance normalized, and the tremor disappeared. One month after valproate discontinuation, his mother thought he had regained his previous level of functioning, and he had lost 22 lb when seen 3 months after discontinuation of sodium valproate. Repeat IQ testing at age 12 years, 5 months showed a full-scale IQ of 92 (Kaufman Adolescents and Adults Intelligence Test). Reading and mathematic aptitudes were at the 37th and 44th percentiles for age (Woodcock-Johnson Psycho-Educational Battery—Revised). Repeat MRI 3 months after valproate discontinuation revealed a substantial decrease in the amount of atrophy. One year later the MRI appeared completely normal (Fig B). Felbamate was replaced by carbamazepine, 500 mg daily. He received pemoline (Cylert), 37.5 mg daily, for his hyperactivity. At age 12 years, 10 months, his condition appeared stable. He has been seizure-free since age 10 years, 7 months.

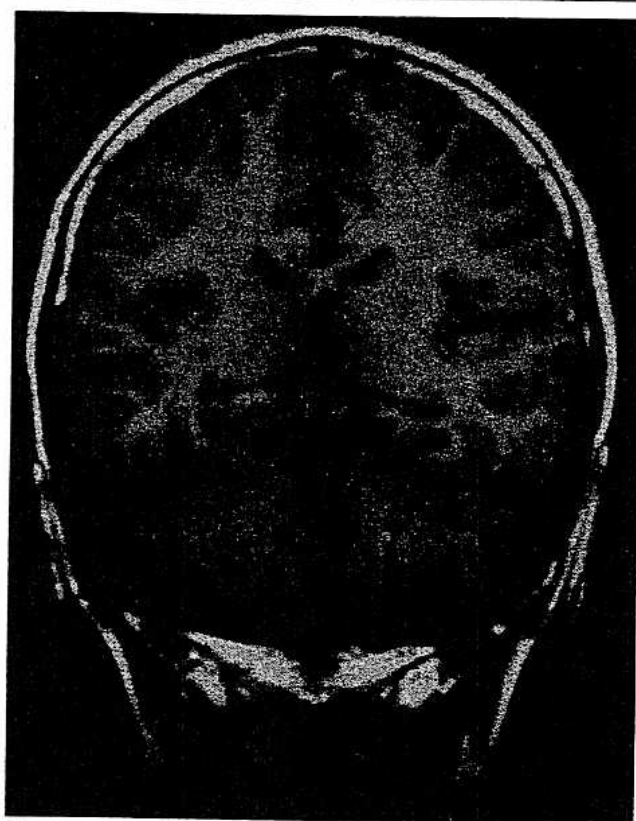
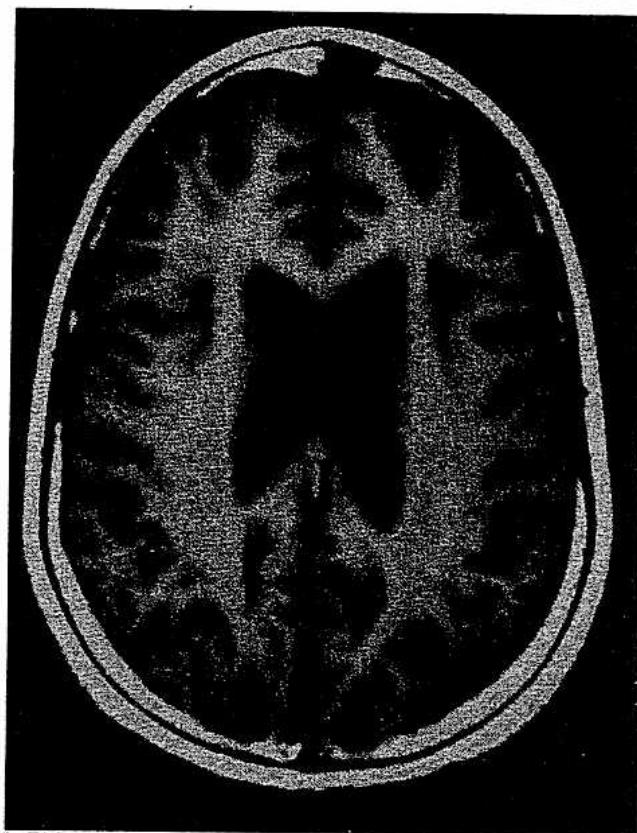
### Patient 2

An 8-year, 5-month-old girl presented with headaches having typical migrainous features. Her motor and mental development were normal. At 3, 4, and 5 years old she had brief seizures lasting only a few seconds that consisted of a feeling of torsion of the tongue with inability to speak but with preserved language comprehension and awareness. Neurological examination was unremarkable and EEG and CT scan of the brain appeared normal. She was placed on carbamazepine, 20 mg/kg/day. She continued to have seizures involving the right upper arm with occasional tonic stiffening of the left lower limb. A repeat EEG 8 months after seizure onset showed paroxysmal sharp waves in the centroparietal area that phase-reversed at T<sub>3</sub>. EEG background activity was normal with the exception of intermittent polymorphic delta activity in the left frontal region. The tracing was compatible with the diagnosis of BRE. Sodium valproate (40 mg/kg/day) was initiated due to poor seizure control at age 9 years, 9 months.

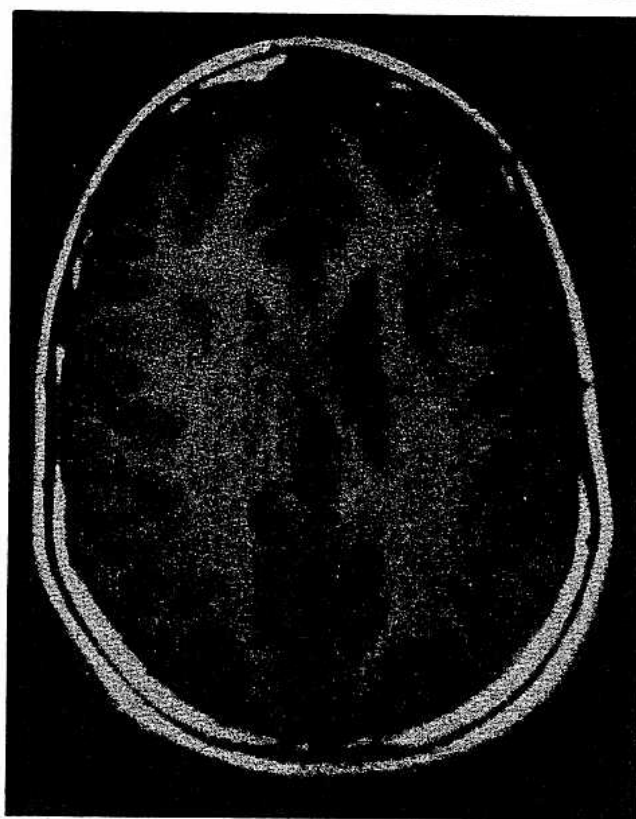
Within 3 weeks, her parents noted increasing drowsiness, emotional lability, and poor concentration. The valproate blood level was 112 mg/dl. Three months later, despite reduction of the dose from 1,000 mg to 750 mg daily, the patient was unable to function satisfactorily at school. Her reading was severely impaired and her writing became slow and illegible. She complained of headache, exhibited a marked tremor, and developed hair loss. Neurological examination revealed truncal ataxia, generalized tremor, and horizontal nystagmus. She remained inactive and disinterested in her surroundings, and had a prominent blank stare; her movements were slow and awkward. A degenerative disorder involving the central nervous system was suspected when MRI showed widespread atrophic changes of the cerebral



A

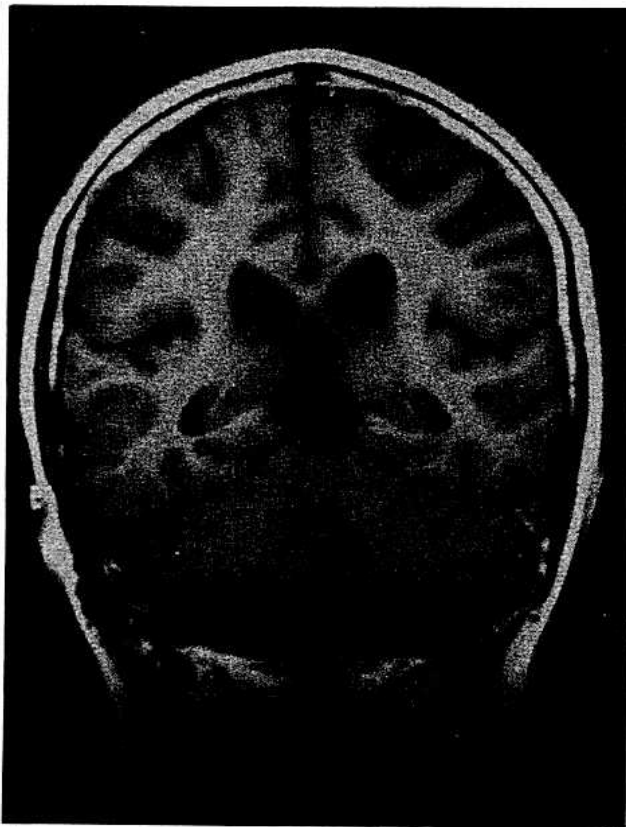

B

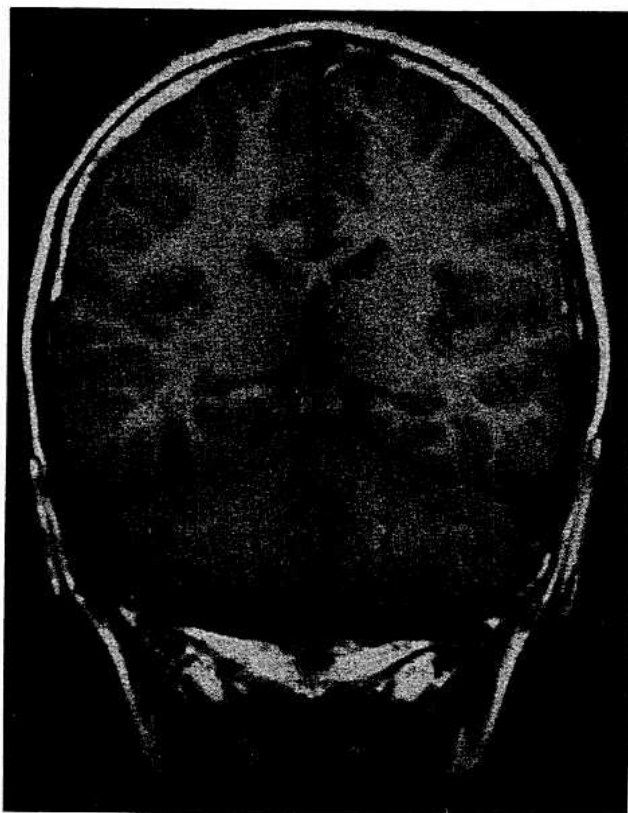
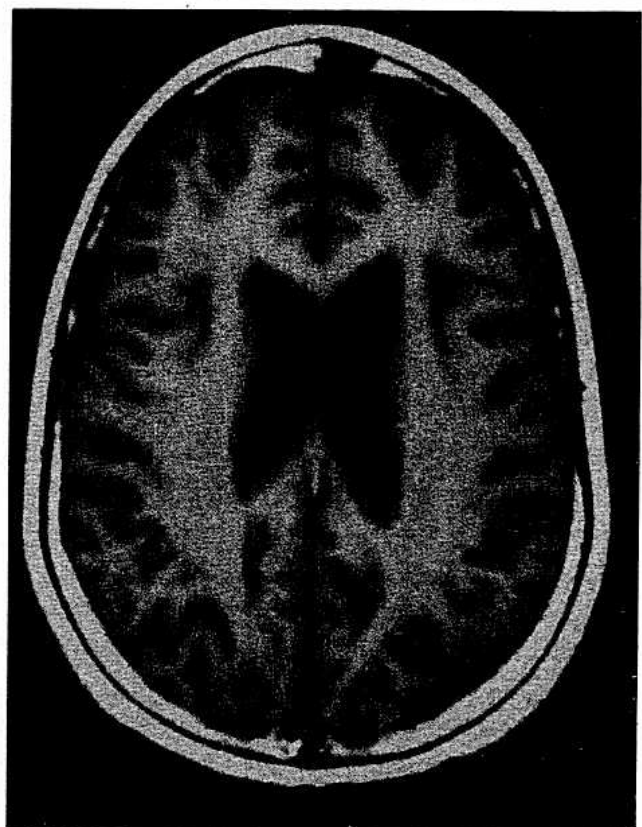


*Magnetic resonance (MR) resolution of cerebellar and cerebral atrophy. (A) Initial axial and coronal T1-weighted MR images demonstrating moderate lateral ventriculomegaly with sulcal and*

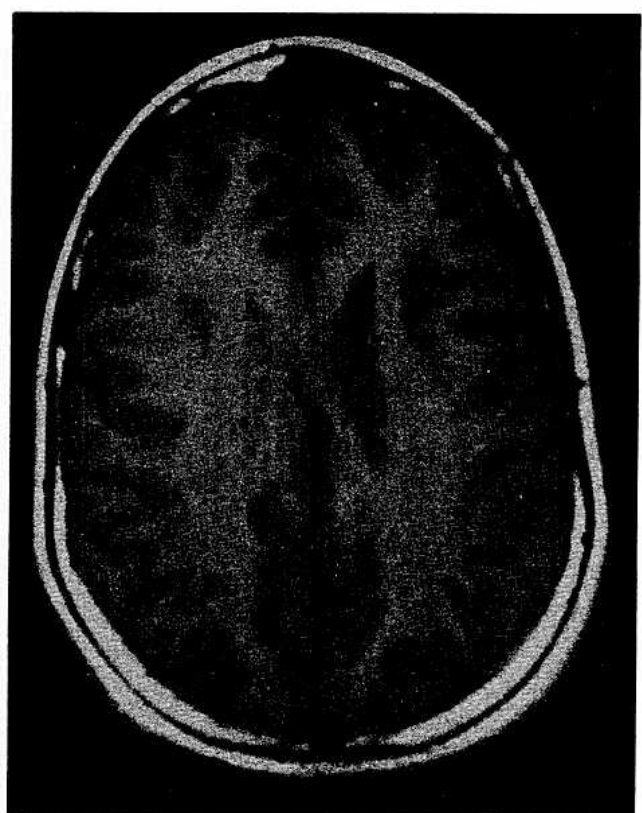
*cerebellar folia prominence. (B) Twelve-month follow-up axial and coronal T1-weighted MR images are normal.*



A



B



Magnetic resonance (MR) resolution of cerebellar and cerebral atrophy. (A) Initial axial and coronal T1-weighted MR images demonstrating moderate lateral ventriculomegaly with sulcal and

cerebellar folia prominence. (B) Twelve-month follow-up axial and coronal T1-weighted MR images are normal.

and cerebellar hemispheres consisting of mildly enlarged ventricles with marked widening of the cortical sulci and increased depth of the pericerebral spaces similar to Patient 1. Cerebrospinal fluid examination was normal. The EEG remained unchanged. Blood free and acyl carnitine, phytanic acid, very-long-chain fatty acid, pyruvic and lactic acid, and ammonia levels and blood and urine amino acid and organic acid levels were normal.

Valproate was replaced by phenobarbital due to toxicity 4 months after onset. During this time she experienced two mild partial seizures. Ataxia and nystagmus disappeared after 1 month, the tremor decreased, and her behavior improved remarkably. Four months after discontinuation of valproate therapy her parents regarded her behavior and mental efficiency as entirely normal. The tremor was no longer demonstrable although some awkwardness of fine-motor activity persisted. Repeat MRI 6 months after withdrawal of valproate appeared normal. Nineteen months after discontinuation of valproate she was physically and mentally normal except for slightly awkward fine movements.

## Discussion

Both patients developed severe cognitive and behavioral regression while being treated with sodium valproate for BRE. Their deterioration was associated with the new appearance of cerebral and cerebellar hemisphere atrophy that had not been observed in baseline imaging studies. The clinical picture was also striking, characterized by a loss of spontaneity and interest in surroundings and emergence of regressive behaviors. Motor inactivity was particularly remarkable in Patient 1 since he had previously been extremely hyperactive. His cognitive deterioration was also severe, with a documented loss of 22 IQ points on serial neuropsychological testing.

The clinical and imaging changes of this condition are sufficiently severe to raise suspicion of a degenerative disease and to mandate extensive metabolic, biochemical, and electrophysiological investigations, despite the preserved normality of EEG background activity and the fact that the electroclinical presentation was consistent with BRE. However, the abnormalities disappeared following withdrawal of valproate, with almost complete clinical recovery in a few weeks. Normalization of the MRI was completed at 6 and 12 months. Both patients also exhibited more common valproate side effects including weight gain, hair loss, and tremor, which also disappeared following discontinuation of valproate therapy.

Both patients' courses were remarkably similar to that of a previously reported adolescent who developed reversible deterioration and "pseudoatrophy" of the central nervous system while on valproic acid treatment [7]. Together, these three case reports confirm that brain atrophy and cognitive deterioration are real, albeit rare, complications of valproate therapy.

Although both of our patients had BRE, we regard this association to be fortuitous. BRE is an exceedingly common disorder that presents in the first decade of life in neurologically normal children, and is not associated with MRI changes [8]. Rather than being progressive, BRE usually responds to antiepileptic drugs and has a favorable prognosis [9]. Furthermore, the patient reported by McLachlan [7] did not have the features of BRE.

Patient 1 was receiving thioridazine and benztropine mesylate concurrent with sodium valproate and both drugs were discontinued along with sodium valproate, so that their role cannot be excluded a priori. However, these agents are not known to produce dementia or brain atrophy, although they can induce drowsiness and even confusion in some patients. Because Patient 2 and the patient reported by McLachlan [7] were taking only sodium valproate, it is also unlikely that other medications were responsible. Our patients are also reminiscent of a young adult who reportedly developed dementia while on valproic acid and recovered on withdrawal, although a CT scan performed at the peak of symptoms was said to be normal [10]. It is possible that cranial CT is insufficient to detect minor atrophy, although the neuropsychological characteristics of this patient were remarkably similar to those in our patients.

The relationship between valproate, brain atrophy, and dementia is likely to be exceedingly complex. Our second patient and the one reported by McLachlan [7] developed symptoms immediately on introduction of valproate therapy, whereas our first patient and the patient of Zaret and Cohen [10] received valproate for long periods before the onset of symptoms (22 months and 4 years, respectively). The doses and blood levels reported were within accepted limits, although levels in the region of 100 mg/dl or more were present in all patients. Changes in dose before onset of symptoms were not mentioned in the report by Zaret and Cohen [10] and were not done in our first patient while asymptomatic on valproate therapy.

We do not have a good explanation for the mechanism of the symptoms and signs of valproate-induced brain atrophy or dementia. Ammonia levels were marginally elevated in our first patient but normal in another patient who was likely to have experienced this complication, although imaging data were lacking [10]. Carnitine levels were also normal in our patients. Most importantly however, during the period of deterioration, the EEG did not show any increase in epileptic paroxysms, as reported in several patients with stupor induced by valproate [11, 12]. Moreover, there was no disturbance of consciousness and no apparent increase in seizure frequency.

Whatever the mechanism, the appearance of neuro-

logical signs or brain atrophy in patients receiving valproate therapy is of great practical importance. In such patients valproate discontinuation should be the first step toward diagnosis, and should be performed before embarking on expensive and exhaustive investigations. This principle holds regardless of duration of valproate administration or measured blood levels. The normality of the EEG background in the face of increasingly severe symptoms may be useful in differentiating valproate-induced brain atrophy and dementia from other progressive conditions including biochemical disturbances and epileptic states. Withdrawal of valproate is usually effective very quickly, with clinical recovery already evident in 2 or 3 weeks.

## References

1. Herranz JL, Armijo JA, Arteaga R. Clinical side effects of phenobarbital, primidone, phenytoin, carbamazepine, and valproate during monotherapy in children. *Epilepsia* 1988;29:794-804
2. Scheffner D, König St, Rauterberg-Ruland I. Fatal liver failure in 16 children with valproate therapy. *Epilepsia* 1988;29:530-542
3. Coulter DL, Allen RJ. Pancreatitis associated with valproic acid therapy. *Ann Neurol* 1980;7:92 (Letter)
4. Brown JK. Valproate Toxicity. *Dev Med Child Neurol* 1988;30:121-125
5. Triggs WJ, Bohan TP, Lin SN, Wilmore LJ. Valproate-induced coma with ketosis and carnitine insufficiency. *Arch Neurol* 1990;47:1131-1133
6. Zaccara G, Paganini M, Camprotrini R, et al. Hyperammonemia and valproate-induced alterations of the state of consciousness. A report of 8 cases. *Eur Neurol* 1984;23:104-112
7. McLachlan RS. Pseudoatrophy of the brain with valproic acid monotherapy. *Can J Neurol Sci* 1987;14:294-296
8. Aicardi J. Benign rolandic epilepsy. *Int Pediatr* 1987;2:176-181
9. Loiseau P, Duché B, Cordova S, et al. Prognosis of benign childhood epilepsy with centrottemporal spikes: a follow-up study of 168 patients. *Epilepsia* 1988;29:229-235
10. Zaret BS, Cohen RA. Reversible valproic acid-induced dementia: a case report. *Epilepsia* 1986;27:234-260
11. Marescaux C, Warter JM, Micheletti G, et al. Stuporous episodes during treatment with sodium valproate: report of seven cases. *Epilepsia* 1982;23:297-305
12. Zaret BS, Beckner RR, Marini AM, et al. Sodium valproate induced hyperammonemia without clinical hepatic dysfunction. *Neurology* 1982;32:206-208

# Oxidative Damage to Protein in Sporadic Motor Neuron Disease Spinal Cord

Pamela J. Shaw, MD, FRCP,\*  
Paul G. Ince, MD, MRCPATH,†§  
Gavin Falkous, MPhil,‡  
and David Mantle, PhD‡

The recent discovery that defects in the gene encoding copper-zinc superoxide dismutase (SOD1) are associated with some cases of familial motor neuron disease has heightened interest in the possibility that free radical mechanisms may contribute to selective motor neuron injury. Sporadic and familial motor neuron diseases are clinically and pathologically very similar and may share common pathophysiological mechanisms. Thus the role of free radical mechanisms as a contributory factor to motor neuron injury in the common sporadic form of motor neuron disease requires urgent exploration, particularly as this may provide an avenue for therapy aimed at retarding pathological progression. We investigated oxidative damage to proteins in the lumbar spinal cord by quantifying the protein carbonyl level from 19 patients with sporadic motor neuron disease, 8 neurologically normal control subjects, and 11 neurological disease control subjects, most of whom had slowly progressive neurodegenerative disease. In sporadic motor neuron disease the mean protein carbonyl level in the spinal cord was increased by 119% ( $p < 0.02$ ) compared to normal control subjects and by 88% ( $p < 0.04$ ) compared to the neurological disease control subjects. These data contribute to the emerging evidence that oxidative damage may play a contributory role in the neuronal death in sporadic motor neuron disease. This mechanism may be particularly important in a subset of patients with motor neuron disease.

Shaw PJ, Ince PG, Falkous G, Mantle D. Oxidative damage to protein in sporadic motor neuron disease spinal cord. *Ann Neurol* 1995;38:691-695

The cause of selective neuronal death in motor neuron disease (MND) has not been established. A major recent development has been the discovery that some

From the \*Departments of Neurology, †Neuropathology, and ‡Neurochemistry and the §MRC Neurochemical Pathology Unit, University of Newcastle upon Tyne, Newcastle upon Tyne, United Kingdom.

Received Mar 14, 1995, and in revised form Jun 21. Accepted for publication Jun 21, 1995.

Address correspondence to Dr Shaw, University Department of Neurology, Ward 11, Royal Victoria Infirmary, Newcastle upon Tyne NE1 4LP, United Kingdom.