

Valproic Acid-Induced Hyperammonemic Encephalopathy: MR Appearance

Mark D. Baganz and Peter E. Dross

Summary: The authors report MR findings in a case of valproic acid-induced hyperammonemia showing high signal intensity on T2-weighted images in frontal, temporal, and insular cortex.

Index terms: Seizures; Brain, magnetic resonance; Brain, diseases; Brain, metabolism; Drugs, toxicity; Iatrogenic disease or disorder

Valproic acid currently is used as an anticonvulsant medication with a broad spectrum of activity. It usually is used in seizures in children and adults that are not controllable by other anticonvulsants. A documented side effect of valproic acid therapy has been the elevation of the serum ammonia level, with the subsequent development of hyperammonemic encephalopathy. We report the brain magnetic resonance (MR) findings of valproic acid-induced hyperammonemic encephalopathy.

Case Report

A 24-year-old man with a 17-year history of a seizure disorder presented to our emergency room with a 2-day history of progressive confusion and disorientation. His seizure disorder had been controlled with long-term valproic acid therapy. While in our emergency room, the patient was noted to have shifting neurologic signs including rigidity, hyperreflexia, and intermittent asterixis. The patient quickly lapsed into a comatose state requiring intubation for respiratory support. Computed tomography (CT) of the brain at admission was normal. Hypoglycemia and hepatic encephalopathy were considered possible causes of the patient's coma, but serum glucose and liver function tests were normal. Serum ammonia was elevated at 388 $\mu\text{mol/L}$, with the normal range being 11 to 35 $\mu\text{mol/L}$. Because of the elevation of serum ammonia, a defect in amino acid metabolism was considered. However, blood carnitine, alanine, and glutamine levels were not elevated. Urinary amino acid assay demonstrated no evidence of a metabolic disorder, including no evidence of elevated urinary orotic acid. The serum valproic acid level

was found to be slightly elevated at 119 $\mu\text{g/mL}$ (therapeutic range at our institution is 50 to 100 $\mu\text{g/mL}$). Toxicity was suspected, and valproic acid therapy was discontinued on the day of admission. The serum ammonia level peaked at 539 $\mu\text{mol/L}$ on the second hospital day and dropped to 52 $\mu\text{mol/L}$ by the third hospital day. Electroencephalography demonstrated a symmetric, high-voltage, slow wave pattern with a background disorganization consistent with a generalized encephalopathy. MR of the brain showed extensive areas of increased T2 signal intensity within the frontal, temporal, and insular cortical regions bilaterally (Fig 1A and B). There were no abnormalities noted on the T1-weighted images, either before or after the administration of intravenous gadopentetate dimeglumine. During hospitalization, the patient improved under conservative therapy, with mental status gradually returning to normal. The patient was discharged on the 27th hospital day in good condition. Follow-up MR of the brain was performed 1 year after discharge and revealed resolution of the previously noted areas of signal abnormality, although some diffuse cortical atrophy was present (Fig 1C and D).

Discussion

Valproic acid, first introduced in the United States in 1978, has since been used as an effective anticonvulsant in a variety of adult and childhood seizure disorders. Although initially thought to be free of serious side effects, several reports have suggested an association between valproic acid use and the occurrence of hepatitis, a Reye-like syndrome, and hyperammonemia (1).

Ammonia is a product of protein and amino acid metabolism. Catabolism of amino acids occurs in the liver (in the cytosol and mitochondria of the hepatocytes) and, to a lesser extent, in the kidneys. The carbon skeletons of amino acids undergo oxidative degradation to compounds that can enter the Krebs's tricarboxylic acid cycle and later be converted into adenosine

Received February 3, 1993; accepted for publication April 16.

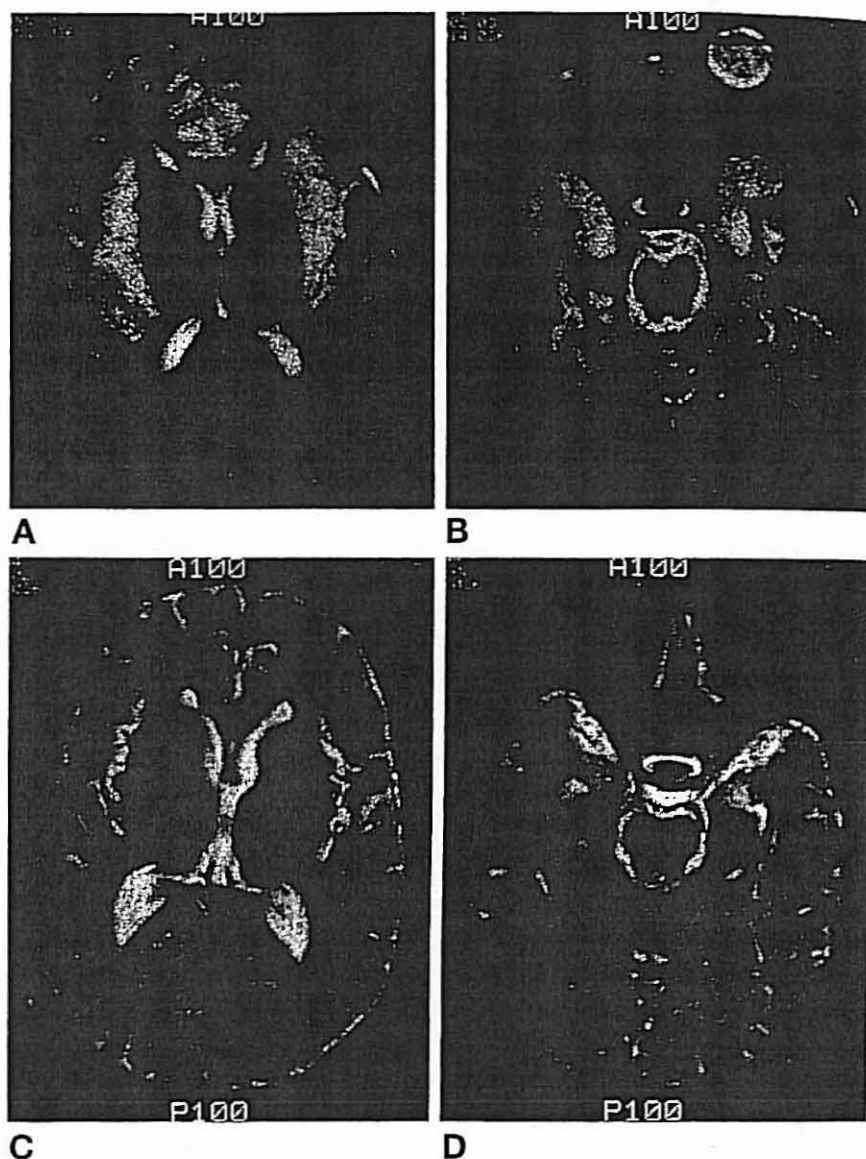
From the Department of Radiology, Medical Center of Delaware, Newark.

Address reprint requests to Mark D Baganz, Department of Radiology, Howard University Hospital, 2041 Georgia Ave, NW, Washington, DC, 20060.

AJNR 15:1779-1781, Oct 1994 0195-6108/94/1509-1779 © American Society of Neuroradiology

Fig 1. **A** and **B**, Axial sections (spin-echo 2800/80) show extensive signal changes of primarily gray matter of frontal, temporal, and insular cortical regions.

C and **D**, Follow-up axial sections (spin-echo 2800/80) at the same levels 1 year after discharge show resolution of cortical signal changes, although now demonstrating mild atrophy.



triphosphate energy sources. The amino groups are removed from amino acids via transamination and oxidative deamination (2, 3), yielding ammonia. The ammonia so formed is metabolized by the hepatic ornithine urea cycle or by detoxification with glutamic acid to form glutamine. The exact mechanism of valproic acid hyperammonemia is unknown, but it appears to be independent of hepatotoxicity (4, 5). Proposed mechanisms include propionic acid (a valproic acid metabolite) inhibition of the urea cycle enzyme carbamoyl phosphate synthetase I (1, 6) or the formation of valproic acid-coenzyme A esters, which prevents the formation of *N*-acetyl-L-glutamate, the obligate activator of carbamoyl phosphate synthetase I (7).

The pharmacokinetics of valproic acid are complex and demonstrate a great degree of interpatient variability. Serum concentration and the development of adverse reactions are influenced by such factors as a variable degree of plasma protein binding and comedication with other anticonvulsants, specifically phenobarbital and phenytoin, which are known to exaggerate the hyperammonemic response in valproic acid-treated patients (8). Dietary protein intake also has been shown to aggravate valproic acid-induced hyperammonemia (7). Patients with congenital or acquired defects of urea synthesis, including ornithine carbamoyl transferase, carbamoyl phosphate synthetase, and argininosuccinate synthetase deficiency are

particularly prone to valproic acid-induced hyperammonemia (9, 10).

Hyperammonemia appears to affect primarily cerebral astrocytes with secondary brain parenchymal damage (9). Astrocytes have been shown to be responsible for brain ammonia detoxification and initially respond to hyperammonemia by increasing metabolic activity through the proliferation of mitochondria and rough endoplasmic reticulum (9, 11). Metabolic exhaustion ensues whereby the astrocyte cytoplasm becomes watery and glycogen laden. Disturbance in the composition of the extracellular fluid and osmotic gradients eventually results in cerebral edema. Elevated levels of glutamine have been found in the cerebrospinal fluid of patients with hyperammonemia and may contribute to brain damage (3). The end stage of the disease is severe cortical and white matter atrophy with Alzheimer type II glia (9, 10, 12).

The CT appearance of hyperammonemic encephalopathy, other than valproic acid induced, has been described previously (9, 10, 13, 14). During an episode of acute encephalopathy, CT findings may be normal or show diffuse brain edema with cerebral white and/or gray matter hypodensities sparing the basal ganglia. The MR appearance of hyperammonemic encephalopathy has been reported in patients with ornithine transcarbamylase deficiency (15-17) and in a patient with uretersigmoidostomy (18). The MR appearance in two of the cases resembled infarcts (16, 17), with the remaining two cases showing variable white matter changes (15, 18). Initial and 4-month follow-up MR in our case support the histopathologic changes described above in the acute encephalopathic and in the chronic (recovered) stages of hyperammonemic brain injury. The MR findings for valproic acid-induced hyperammonemic encephalopathy in our case do not match the changes observed in non-valproic acid-induced hyperammonemic encephalopathy. This suggests that perhaps a varying duration of hyperammonemia, as well as differing serum ammonia concentrations, will result in varying degrees of

severity and location of brain injury. Cerebral hypoperfusion secondary to elevated intracranial pressure also may play an important role in affecting brain injury.

References

1. Powell-Jackson PR, Tredger JM, Williams R. Hepatotoxicity to sodium valproate: a review. *Gut* 1984;25:673-681
2. Devlin TM. *Textbook of Biochemistry with Clinical Correlations*. New York: Wiley-Liss Inc; 1992:475-525
3. Stryer L. *Biochemistry*. New York: WH Freeman & Co; 1988:495-515
4. Zaret BS, Beckner RR, Marini AM, Wagle W, Parsarelli C. Valproate-induced hyperammonemia without clinical hepatic dysfunction. *Neurology* 1982;32:206-208
5. Coulter DL, Allen RJ. Hyperammonemia with valproic acid therapy. *J Pediatr* 1981;99:317-319
6. Coulter DL, Allen RJ. Secondary hyperammonemia: a possible mechanism for valproate encephalopathy. *Lancet* 1980;2:1310-1311
7. Marini AM, Zaret BS, Beckner RR. Hepatic and renal contributions to valproic acid induced hyperammonemia. *Neurology* 1988;38:365-371
8. Gal P, Oles KS, Gikman JT, Weaver R. Valproic acid efficacy, toxicity and pharmacokinetics in neonates with intractable seizures. *Neurology* 1988;38:467-471
9. Dolman CL, Clasen RA, Dorovini-Zis K. Severe cerebral damage in ornithine transcarbamylase deficiency. *Clin Neuropathol* 1988;7:10-15
10. Kendall BE, Kingsley DPE, Leonard DV, Lingam S, Oberholzer VG. Neurological features and computed tomography of the brain in children with ornithine transcarbamylase deficiency. *J Neurol Neurosurg Psychiatry* 1983;46:28-34
11. Norenberg MD. A light and electron microscopic study of experimental portal-systemic (ammonia) encephalopathy: progression and reversal of the disorder. *Lab Invest* 1977;36:618-627
12. Bruton CJ, Corsellis JAN, Russell A. Hereditary hyperammonemia. *Brain* 1980;93:423-434
13. Edwards RH. Hyperammonemic encephalopathy related to uretersigmoidostomy. *Arch Neurol* 1984;41:1211-1212
14. Olier J, Gallego J, Digon E. Computerized tomography in primary hyperammonemia. *Neuroradiology* 1989;31:356-357
15. Mirowitz SA, Saitor K, Prensky AJ, Gado M, Hodges FJ. Neurodegenerative diseases of childhood: MR and CT evaluation. *J Comput Assist Tomogr* 1991;15:210
16. Mamourian AC, du Plessis A. Urea cycle defect: a case with MR and CT findings resembling infarct. *Pediatr Radiol* 1991;21:594-595
17. de Graw TJ, Smit LM, Brockstedt M, Meijer Y, Klei-von Moorsel J, Jacobs C. Acute hemiparesis as the presenting sign in a heterozygote for ornithine transcarbamylase deficiency. *Neuropediatrics* 1990;21:133-135
18. Gilbert GJ. Acute ammonia intoxication 37 years after uretersigmoidostomy. *South Med J* 1988;81:1443-1445