

ECT - Brain Damage - Ferraro

13

THE AMERICAN JOURNAL OF PSYCHIATRY

PUBLISHED BY
THE AMERICAN PSYCHIATRIC ASSOCIATION

EDITOR

CLARENCE B. FARRAR, M.D.
113 St. Clair Avenue West, Toronto 5, Ont.

ASSOCIATE EDITORS

WILLIAM RUSH DUNTON, JR., M.D.	KARL M. BOWMAN, M.D.
FRANKLIN G. EBAUGH, M.D.	THEOPHILE RAPHAEL, M.D.
STANLEY COBB, M.D.	WALTER L. TREADWAY, M.D.
WILLIAM C. SANDY, M.D.	JOHN C. WHITEHORN, M.D.
S. SPAFFORD ACKERLY, M.D.	C. CHARLES BURLINGAME, M.D.
LEO KANNER, M.D.	CLARENCE P. OBERNDORF, M.D.

EDITORIAL ASSISTANT

MARTHA V. LAVELL, M.S.S.

FORMER EDITORS

1844-1931

AMARIAH BRIGHAM, M.D.	T. ROMEYN BECK, M.D.	JOHN P. GRAY, M.D.
G. ALDER BLUMER, M.D.	RICHARD DEWEY, M.D.	HENRY M. HURD, M.D.
	EDWARD N. BRUSH, M.D.	

VOLUME 106

"The care of the human mind is the most noble branch of medicine."—GROTIUS

BALTIMORE

1949-1950

CEREBRAL MORPHOLOGIC CHANGES IN MONKEYS SUBJECTED TO A LARGE NUMBER OF ELECTRICALLY INDUCED CONVULSIONS (32-100)¹

ARMANDO FERRARO, M. D., AND LEON ROIZIN, M. D.²
New York City

During the last few years several controversial reports have been published concerning the effects of electrically induced convulsions in human subjects and animals.

To clarify such results presumably related to different technical and experimental approaches, 21 *Maccacus rhesus* monkeys were subjected to experimentally induced convulsions, varying in number and in duration and intensity of the current flow. Two different types of electrodes, small and large, were used.

EXPERIMENTAL PROCEDURE

Maccacus rhesus monkeys (of both sexes) weighing from 5 to 7 pounds were used. The animals were clinically checked up and carefully selected to avoid particularly pre-existing nutritional deficiencies. They were carefully supervised in the course of the experiment as far as appetite and diets are concerned in view of the fact that mild or subclinical vitamin B₁ (or some of the B_c group), C, and more seldom K deficiencies

TABLE 1

Mon-key group	N	Vol-tage	Current flow time, seconds	Num-ber of shocks	Remarks
A	2	90.	0.5	32	Generalized convulsions with incontinence of urine and feces
B	2	90.	0.5	48	" " "
C	2	90.	0.3	64	" " "
D	2	90.	0.3	74	" " "
E	3	90.	0.3	100	" " "

In a previous study we have reported our findings in a group of 10 monkeys subjected to treatment, which from the standpoint of number of convulsions and intensity and voltage of the current we considered close to the therapeutic doses in human beings.

Here we are reporting the findings observed in a group of 11 *Maccacus rhesus* monkeys subjected to from 32 to 100 electric convulsive shocks. This investigation seems to us particularly timely in view of the fact that some psychiatrists feel that for an "adequate" electric shock treatment (2-3) some patients must be treated with a large number of shocks and whenever relapses occur over periods of months.

¹ Presented at the annual meeting of the American Neurological Association, June 16th, 1948, Atlantic City, New Jersey.

² Department of Neuropathology, New York State Psychiatric Institute.

may facilitate or accelerate some structural changes.

The details concerning the induction of convulsions with Rahm's 60-cycle apparatus are summarized in Table 1. The same apparatus was used for ECT in human subjects with the exception of the size of the electrodes. In one group of animals the diameter was reduced to approximately 2 square cm.; in a second group, the diameter measured 7×2 cm. and was adapted to the head of the monkey in such a manner as to cover both sides of the skull from the frontal to the occipital poles.

The animals were sacrificed at intervals varying from ½ hour to over 1½ years after the last induced convulsion. All the monkeys were sacrificed by ether and the necropsy material was fixed immediately in 95% alcohol, 10% neutral formalin and formol-bromide. The standard neuropathologic

S SUBJECTED INDUCED

M. D.²

L. PROCEDURE

keys (of both sexes) pounds were used. The checked up and care- particularly pre-exist- cies. They were care- course of the ex- appetite and diets are the fact that mild or (or some of the B₆ seldom K deficiencies

ce of urine and feces

"
"
"
"

rate some structural

ing the induction of s 60-cycle apparatus e 1. The same appa- in human subjects he size of the elec- f animals the diam- roximately 2 square the diameter mea- as adapted to the uch a manner as to ull from the frontal

rificed at intervals over 1½ years after. n. All the monkeys and the necropsy mediately in 95% malin and formol- d neuropathologic

techniques were used including staining for nerve cells (Nissl), staining for general studies (hemotoxylin and eosin), impregnation for glia elements (Hortega's and Cajal's methods), myelin sheaths and lipide products of disintegration (Roizin's combined method), impregnation for nerve fibers (Biel-schowsky, Bodian) and staining of fatty products of degeneration (Sudan III and Sudan black). From each brain blocks were selected from the frontal pole, precentral and central convolutions, parietal, occipital, temporal lobes (including Ammon's horn) and island of Reil, basal ganglia and hypothalamus, mesencephalon, pons, medulla oblongata, cerebellum, and spinal cord (mostly cervical region). Celloidin blocks (used mostly for cytological studies) were frequently cut serially.

CLINICAL OBSERVATIONS

In all the monkeys the convulsions were induced with potential of 90 volts and with a current flow time of 0.5 sec. (groups A and B) and 0.3 sec. (groups C, D, and E). This procedure induced in Maccacus rhesus monkeys the most constant type of grand mal seizures, whereas a potential of 70 volts with a shorter current flow often resulted in only a petit mal seizure.

The grand mal seizure consisted of a generalized tonic phase followed, after a few seconds, by a generalized clonic one with irregular breathing, ending in apnoea lasting a few seconds. During the tonic and clonic phases marked mucoserous salivation mixed frequently with blood and incontinence of urine and feces were frequently observed. The pupils appeared at times markedly miotic, at others, midriatic (more frequently this phenomenon was observed immediately before the animals regained consciousness). Nystagmus in vertical and horizontal direction was also quite often noticed as well as conjugate deviation of the eyes in upward direction without any lateral predominance. Generally, after the apnoea, there followed a short period of agitation which at times assumed the character of localized disorderly and aimless movements. Following this stage, marked muscular twitches or contractions of the body, extremities, or face and eyelids frequently

appeared. With the small-size electrodes, the tonic-clonic phase lasted, in general, from a few seconds to one minute approximately. With the large-size electrodes, the tonic-clonic phase lasted, usually, longer (from 35 to 40 seconds to 1½ to 2 minutes). During the first tonic and clonic phases of the seizures, as well as throughout the period of apnoea and a few minutes afterwards, the animals were completely unconscious. They then gradually regained consciousness still remaining, however, somewhat confused and disoriented for a further short period of time. In the postconvulsive stage most of the animals disclosed hyperexcitability and hyperactivity of the deep reflexes. With the large electrodes the animals presented at times more pronounced variations in size of the diameter of the pupils (more frequently, however, midriasis) with marked contractions of the various muscles of the face and mouth, protrusion of the tongue, more marked mucous or serous salivation, and automatic mastication (at times lasting for one minute or more). Through all the period of the convulsion until complete consciousness was regained the animal was properly held and protected from trauma.

NEUROPATHOLOGIC FINDINGS

Group A.—(Small electrodes, 32 shocks.) Of the 2 animals, one was sacrificed 24 hours after the last induced convulsion and the other 18 months later.

Macroscopically, in both animals grossly, the brain mesencephalon, pons, medulla, cerebellum, and various segments of the spinal cord appeared normal in color, consistence, and vascularization. No subarachnoid, pial, or intracerebral hemorrhages were grossly noticed.

Microscopically, the cytoarchitecture of the different regions of the cortex appeared normal. Now and then however, moderate nerve cell rarefaction which, at times, resulted in small circumscribed acellular areas, generally distributed around or in the vicinity of blood vessels, was observed. The individual nerve cells appeared pretty well outlined though the Nissl bodies were, at times, indistinct and rather pale and the cell nucleus somewhat deeply stained. This occurred mostly in the frontal and parietal

lobes, at times in the temporal lobe and island of Reil and, only occasionally, in the occipital lobe.

The nerve cells of the various diencephalic nuclear formations appeared frequently irregular in shape. Their cytoplasm was often unevenly stained, with the Nissl bodies displaced toward the periphery or condensed in a more limited portion of the cell's body. The nerve cells of the basal ganglia, or subcortical nuclear formations, mesencephalon, pons, medulla, cerebellum, and spinal cord disclosed no significant morphologic alterations.

The blood vessels, in Nissl and hematoxylin and eosin preparations, did not reveal marked structural changes. However, here and there, some of them appeared somewhat distended or irregular in outline and with perivascular spaces enlarged. Quite frequently they were surrounded by increased number of glia nuclei (Fig. 1), with, at times, macrophages containing yellowish or greenish granular material.

Hortega's silver carbonate method for oligodendroglia and microglia disclosed, in the same areas, slight reactive proliferation and occasionally swelling of the former.

Cajal's gold sublimate method revealed some hypertrophy and hyperplasia of astrocytes, especially around blood vessels and more often in the subcortical white matter of the frontal and parietal lobes, at times in the corpus striatum or thalamus and only occasionally in the temporal lobes.

Nerve fibers and myelin sheaths did not disclose significant changes.

Group B.—(Small electrodes, 48 shocks.) Of the 2 monkeys belonging to this group, one (E13) was sacrificed $\frac{1}{2}$ hour after the last shock treatment and the other (E15), 24 hours later.

Grossly, the pia meninge of E13 appeared more markedly congested than that of E15. The same difference was evidenced in the brain parenchyma. The rest of the central nervous tissue appeared grossly normal.

Microscopically, the cytoarchitecture of the various regions of the cortex appeared fundamentally normal. However, here and there, some rarefaction of neurones and small acellular areas were noticed. The latter were generally confined to the immediate vicinity of blood vessels or sur-

rounding them. Some of the nerve cells belonging to these small circumscribed areas showed various degrees of chromatolysis. Quite often, in the central portion of such areas, dilated blood vessels with enlarged perivascular spaces were seen, particularly in E13. In this case and to a lesser extent in E15 increased numbers of glia nuclei around the enlarged perivascular spaces were prominent, mixed at times with compound granular corpuscles. Frequently the latter contained a fine irregular amorphous, commonly granularlike material which in Nissl preparations stained greenish or yellowish, and with hematoxylin and eosin brownish or yellowish. In the white matter the combined Roizin's method as well as Sudan III and Sudan black disclosed, at times, in the enlarged perivascular spaces or occasionally infiltrating the blood vessel walls, fatty products of degeneration, frequently incorporated in large phagocytic elements (Fig. 2).

In these areas, Hortega's silver carbonate impregnation revealed swollen oligodendroglia cells and proliferation of microglia elements. Correspondingly, mostly in the white matter, hypertrophy and hyperplasia of astrocytes was evidenced by Cajal's gold sublimate impregnation.

The above-mentioned microscopic findings were observed more frequently in the frontal and parietal lobes, more seldom in the temporal and only occasionally in the occipital lobes, and to a lesser extent, here and there, in the corpus striatum and diencephalon. Nerve fibers and myelin sheaths throughout the central nervous system were not altered except when surrounding some enlarged perivascular areas where they appeared somewhat pale and occasionally slightly rarefied.

Group C.—(Small electrodes, 64 shocks.) Monkeys E21 and E20 were respectively sacrificed 48 hours and 1 week following the last electric convulsion.

Grossly, the viscera as well as the central nervous system did not disclose significant changes.

Microscopically, here and there, in the cortex of the frontal and parietal lobes, and, to a lesser extent, in the temporal (including the island of Reil), and occipital lobes, small irregular areas of rarefaction and occasion-

Some of the nerve cells show small circumscribed areas of degrees of chromatolysis. In the central portion of such blood vessels with enlarged perivascular spaces were seen, particularly in this case and to a lesser extent in the other, increased numbers of glia nuclei and enlarged perivascular spaces, mixed at times with corpora amylacea. Frequently the perivascular spaces contain a fine irregular amorphous, mottled material which in sections stained greenish or yellowish with hematoxylin and eosin. In the white matter Roizin's method as well as Sudan black disclosed, at least in some cases, enlarged perivascular spaces or dilated blood vessel lumens, often containing products of degeneration, frequently associated with large phagocytic cells.

In the cortex, Horte's silver carbonate method revealed swollen oligodendrocytes and proliferation of microglia, especially in the white matter. Hyperplasia of microglia and hyperplasia of astrocytes, as evidenced by Cajal's gold method, were also present.

In the mentioned microscopic findings were more frequently in the frontal lobes, more seldom in the parietal lobes, and only occasionally in the occipital lobes. To a lesser extent, here and there, in the corpus striatum and diencephalon, the fibers and myelin sheaths in the central nervous system were present when surrounding some of the cellular areas where they appeared pale and occasionally

small electrodes, 64 shocks.) and E20 were respectively 1 and 1 week following the lesion.

Sections as well as the central sections did not disclose significant

changes, here and there, in the frontal and parietal lobes, and, in the temporal (including the hippocampus), and occipital lobes, small areas of rarefaction and occasion-

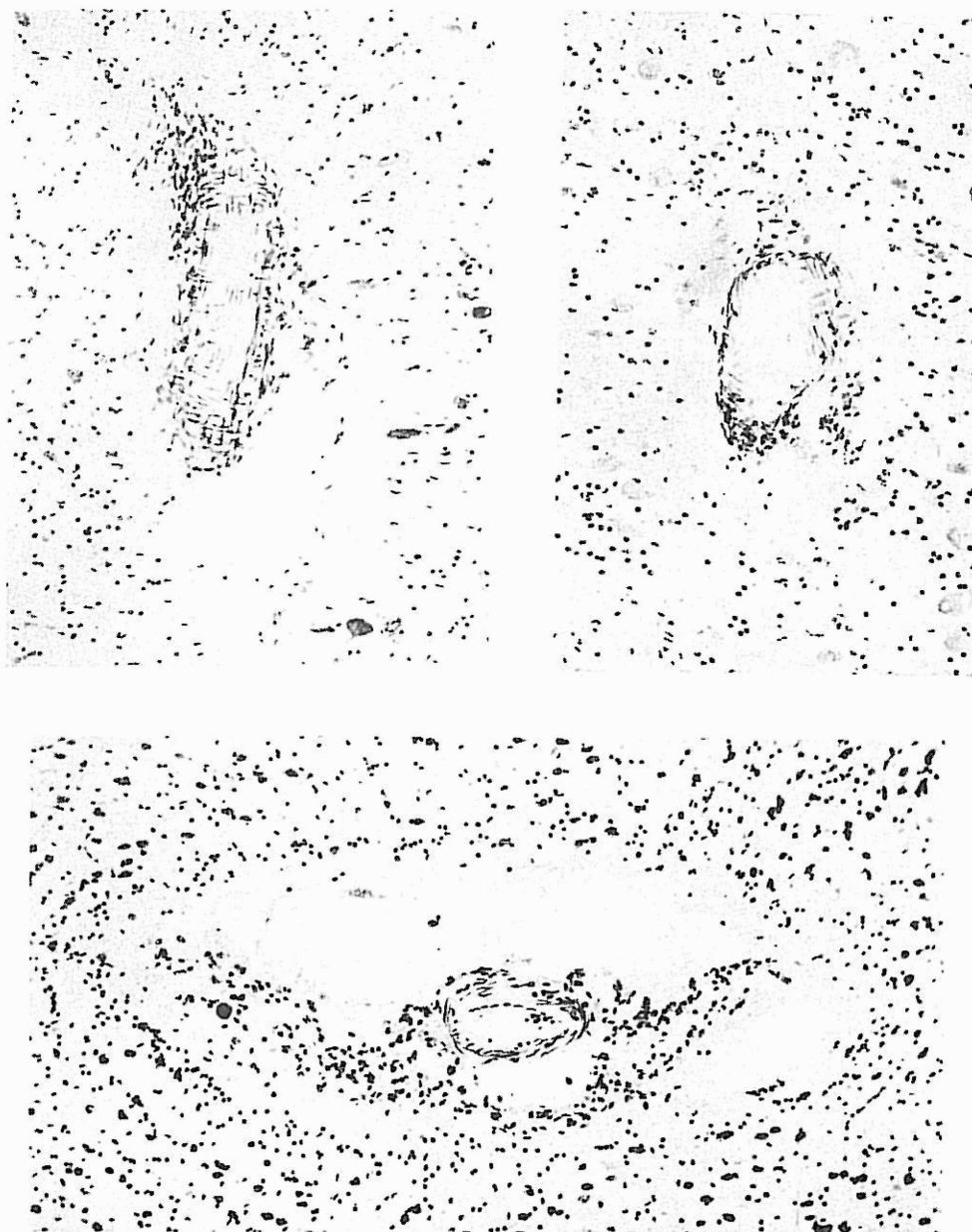

FIG. 1.—Vascular dilatation, enlargement of the perivascular spaces and presence of small and large mononuclear elements within the blood vessel walls and the perivascular spaces. Nissl stain. Medium power magnification.

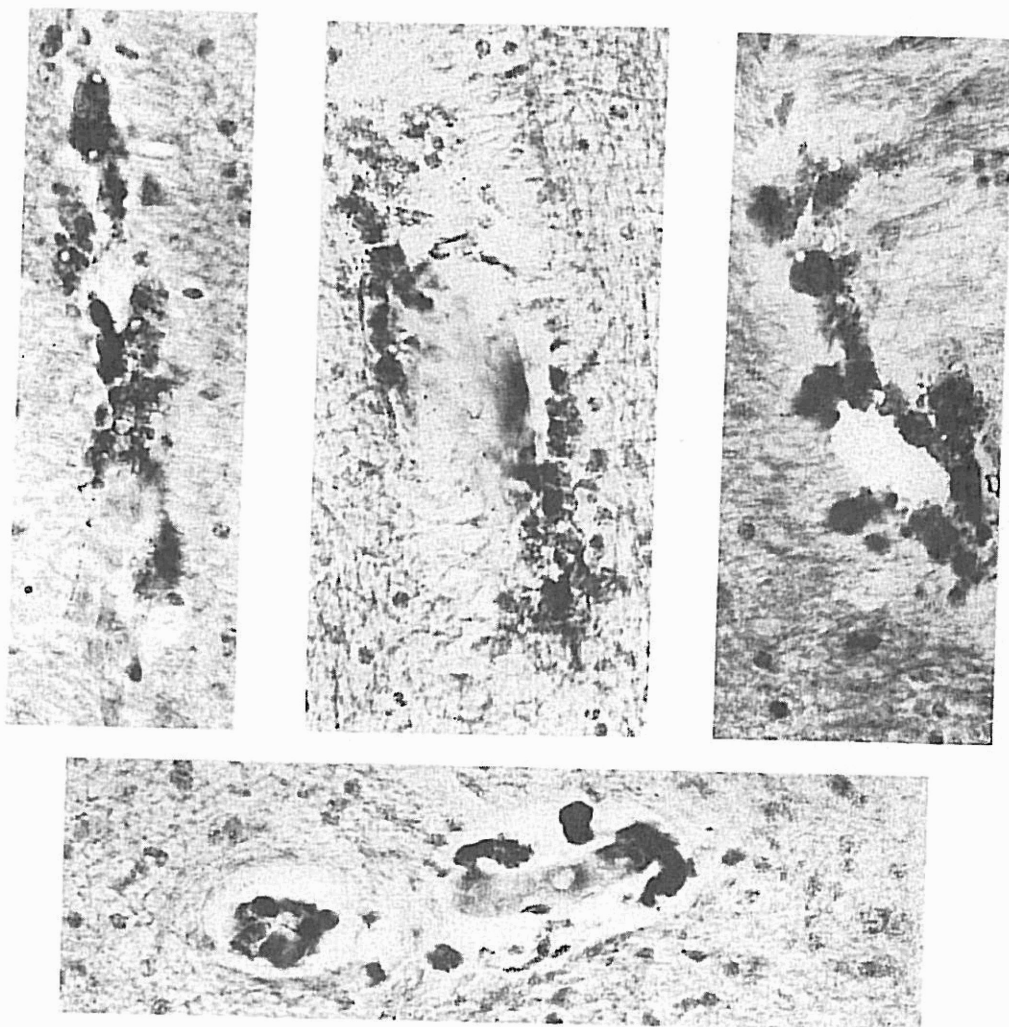
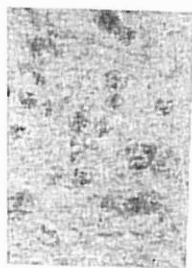
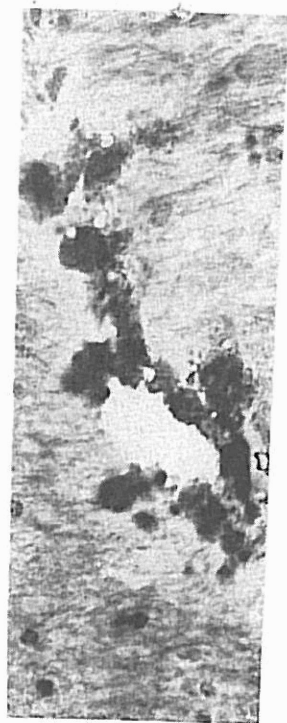
FIG. 2.—Various microscopic fields illustrating the presence of fatty material infiltrating the blood vessel walls and the perivascular spaces; some of it incorporated in compound granular corpuscles. Sudan III stain. Medium power magnification.




FIG. 3.—Circumscribed areas of cell rarefaction and dropping of nerve cells around blood vessels functionally and structurally altered. Nissl stain. Low power magnification.



ty material infil-
it incorporated in
gnification.



d vessels functionally and struc-

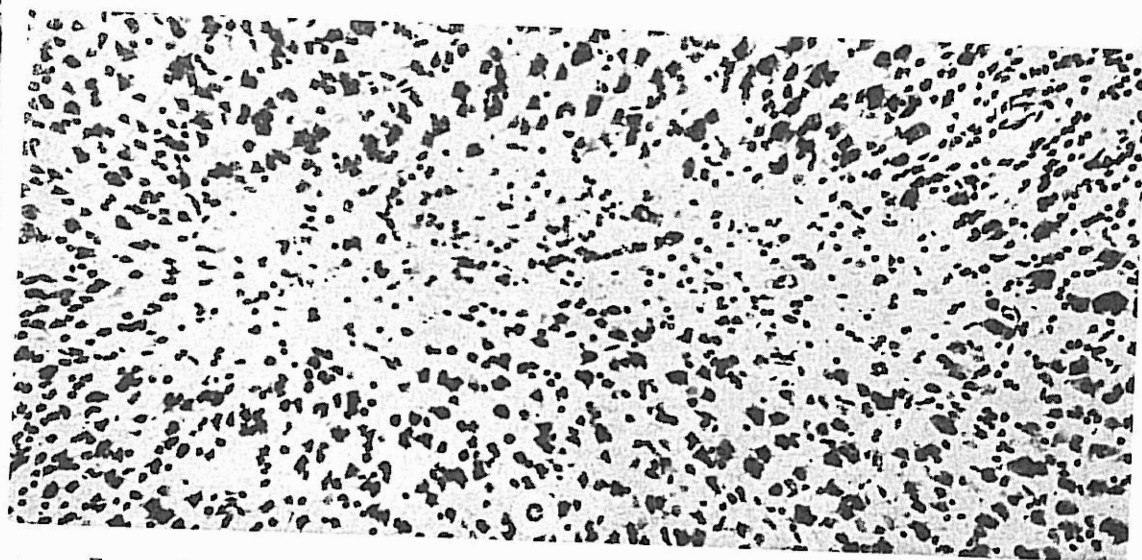
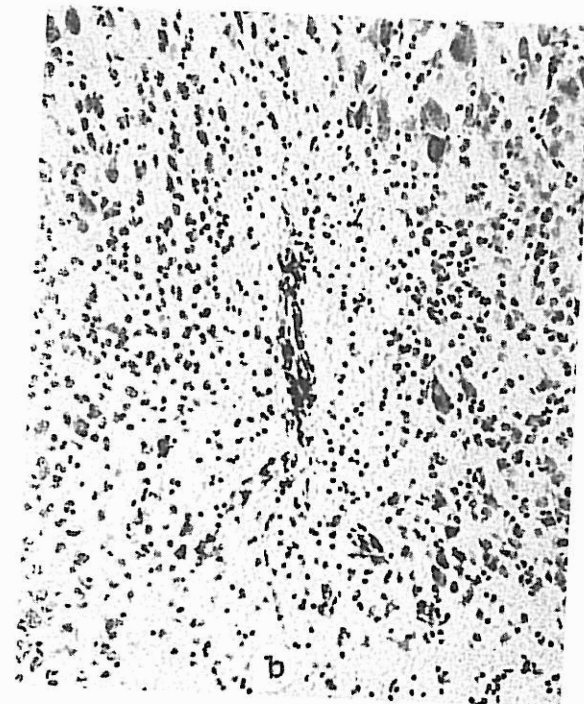



FIG. 4.—Small acellular areas, (a) cortex, (b) diencephalon. Increased glia nuclei proliferation. Nissl stain. Low power magnification. (c)—detail of (a) under higher power magnification.

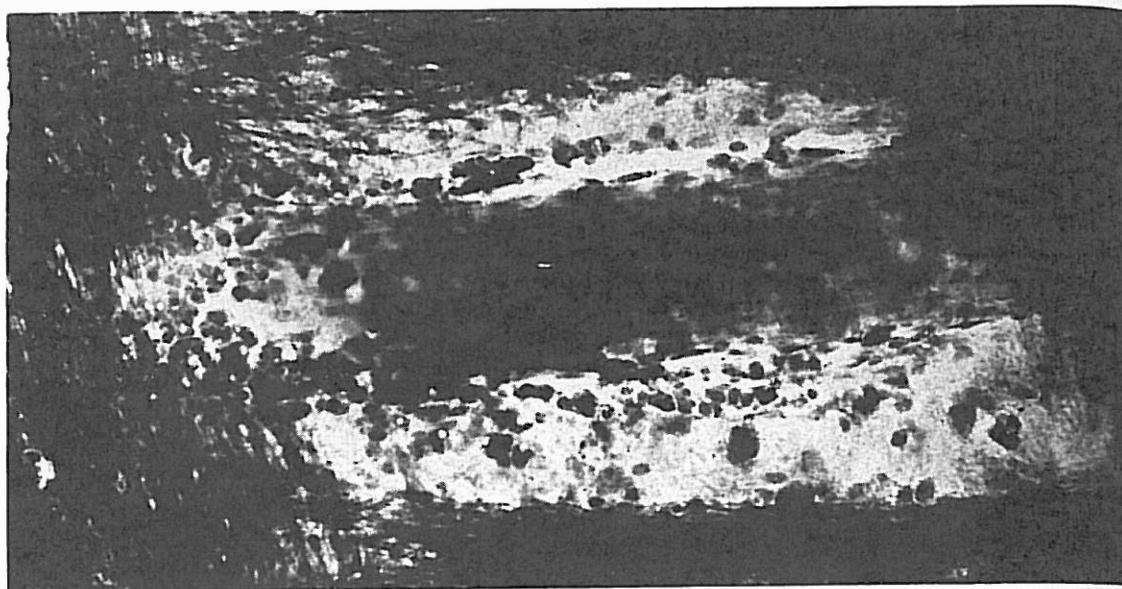


FIG. 5.—Marked perivascular dilatation revealing small mononuclear elements and macrophages containing lipid products of disintegration. (Note also slight rarefaction and pallor of the myelin sheaths in the right field.) Roizin's combined method. Low power magnification.

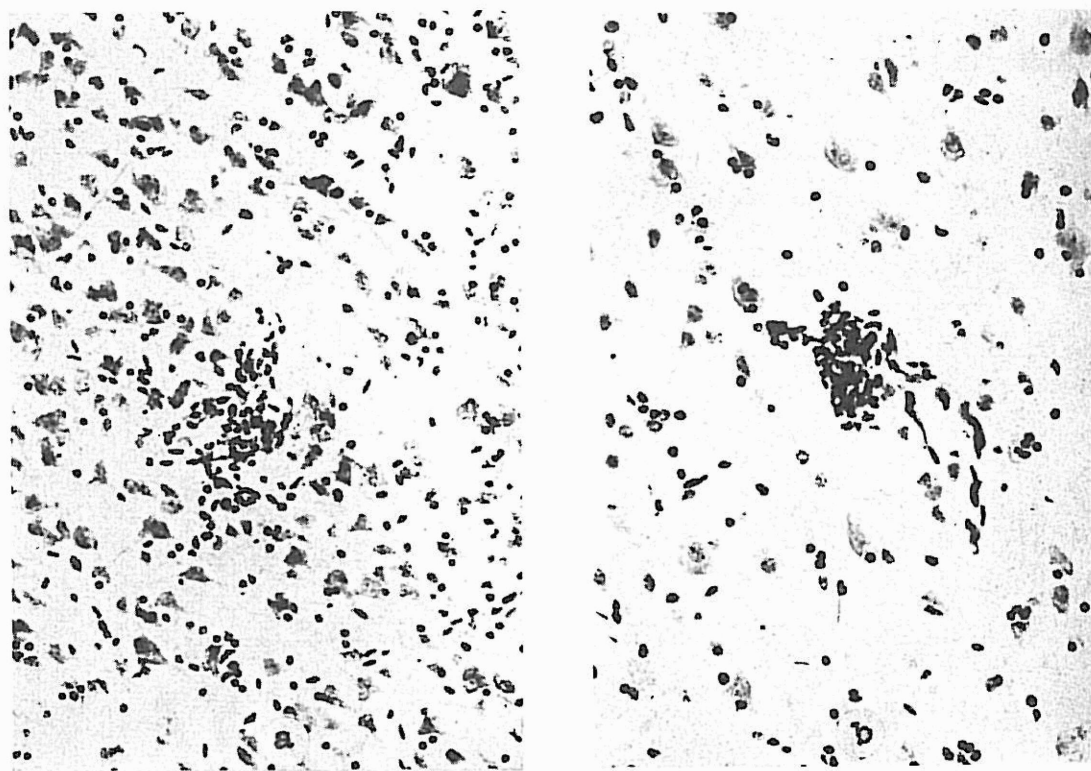
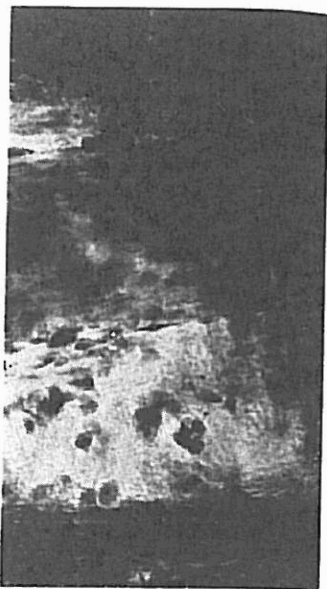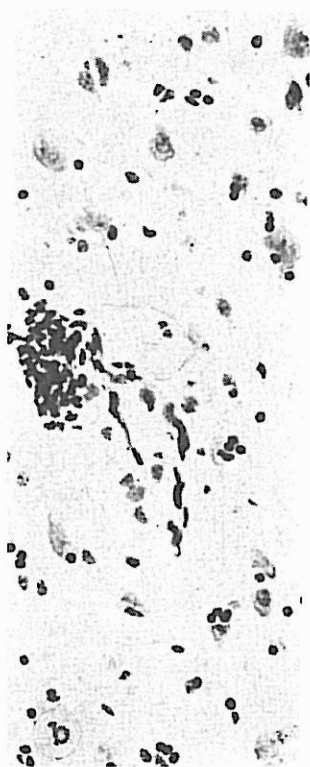


FIG. 6.—Two small petechial hemorrhages in the gray matter, (a) frontal lobe, (b) hypothalamus. Nissl stain. Medium power magnification.



ts and macrophages containing yelin sheaths in the right field.)



a) frontal lobe, ication.

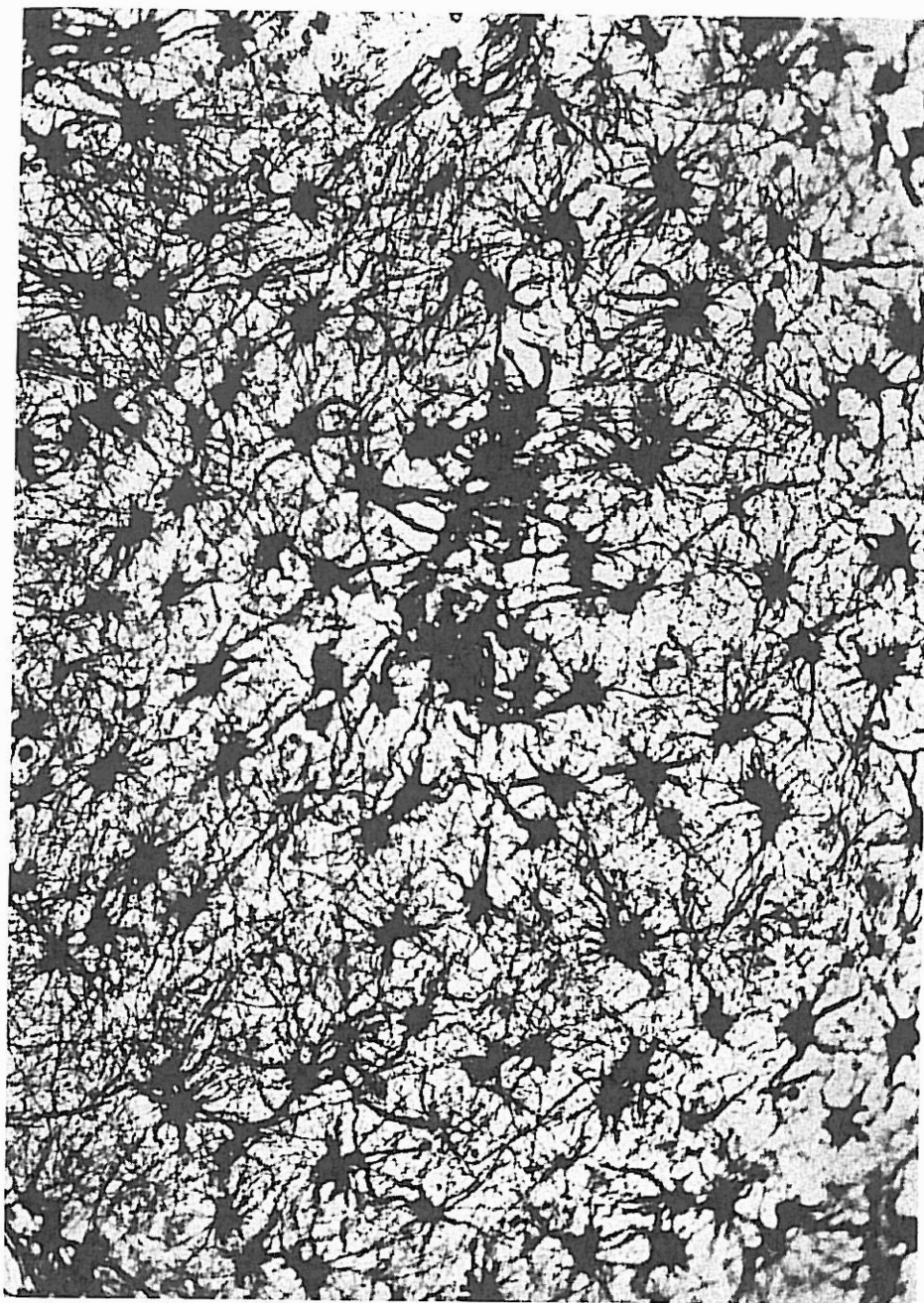


FIG. 7.—Marked hypertrophy and hyperplasia of astrocytes surrounding an irregularly dilated blood vessel. Cajal's gold sublimate impregnation. Medium power magnification.

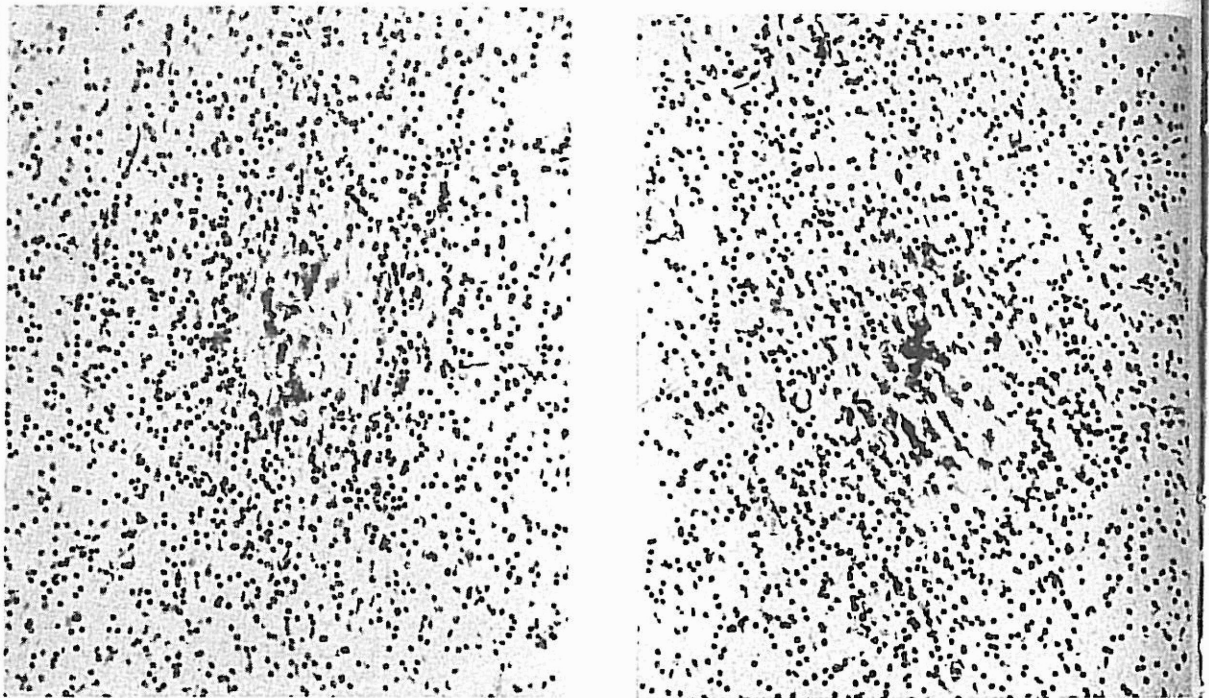


FIG. 8.—Centrum semiovalis: Two areas of increased glia nuclei. Predominance of oligodendroglia. Note in the central portion amorphous material also in large mononuclear elements. Nissl stain. Medium power magnification.

ally acellular areas were observed. As in the previous cases, these findings generally followed the course of a blood vessel (Fig. 3). Similar changes were observed in the basal ganglia and, at times, in the hypothalamus.

In Nissl as well as in hematoxylin and eosin preparations, metachromatic bodies of pinkish, yellowish, and, at times, bluish coloring were observed scattered throughout the white matter, particularly of the frontal, parietal, and temporal lobes. Silver impregnation techniques for nerve fibers as well as myelin sheath stains did not reveal any significant structural alterations.

Group D.—(Large size electrodes, 74 shocks.) Monkeys E14 and E17 were sacrificed respectively 24 hours and 8 days following the last induced convulsion.

Grossly the viscera as well as the central nervous structures did not disclose significant alterations. The pial blood vessels and some ramifications of the anterior and middle cerebral arteries of E14 appeared more dilated and slightly more congested than in E17.

Microscopically the cytoarchitecture of the various cortical regions of the brain as a whole appeared pretty well preserved. However, careful serial section study revealed limited neuronal rarefaction, and occasionally slight cytoarchitectural irregularity. In these monkeys, more so in E17, some irregular stratification of the neurons in the Sommer's sector of Ammon's horn was noticed. In E14 irregular distribution of Purkinje cells was also encountered. In addition, small acellular areas (Fig. 4) were seen mostly in the vicinity or surrounding some blood vessels. The latter appeared dilated and, at times, disclosed irregular pattern or tortuosity. The perivascular spaces often appeared enlarged surrounded by increased glia nuclei frequently mixed with compound granular corpuscles containing a granular material at times siderophile, at others, fatty in nature. Roizin's combined method revealed in a few areas some rarefaction of myelin sheaths and large lipid-containing macrophages (Fig. 5) around enlarged perivascular spaces.

These morphologic changes although limited to small areas, commonly related to the vascular pattern, were scattered in the

various lobes of the brain as well as in the basal ganglia and diencephalon. In addition, in monkey E14, two small areas were found where diapedesis of the morphologic elements of the blood resulted in small petechial hemorrhages (Fig. 6).

Reactive proliferation of the glia elements around some blood vessels was prominent in some areas. Cajal's gold sublimate method disclosed marked hypertrophy and hyperplasia of the astrocytes in areas around blood vessels (Fig. 7). In addition, one gained the impression that, throughout the whole brain and especially in the immediate subcortical regions, the astrocytes were better impregnated than in nontreated animals. Bielschowsky's and Bodian's silver impregnations did not disclose significant morphologic alterations of axis cylinders.

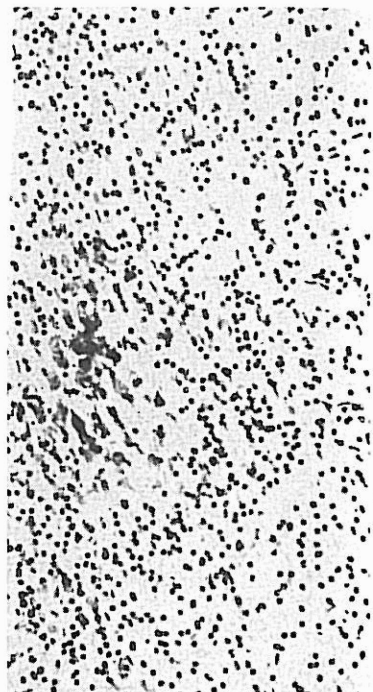
Group E.—(Small size electrodes, 100 shocks.) Monkeys E18, E19, and E16 were sacrificed respectively 7 days, 1 year, and 1½ years after the last induced convulsion.

Macroscopically the viscera as well as the central nervous structures did not reveal significant changes.

Microscopical findings were in part similar to those observed in the monkeys of the C and D group. Serial section studies disclosed mostly in the frontal lobes and, to a lesser extent, in the parietal and temporal lobes, mild neuronal rarefaction or small acellular areas surrounding blood vessels or in their immediate vicinity. In areas of the cortex of the island of Reil and in the Sommer's sector of Ammon's horn scattered loss of nerve cells and dropping of neurons and slight irregularity in cellular stratification were also noticed.

Tortuosity and irregular enlargement of some cortical and subcortical blood vessels was present. Some of the blood vessels disclosed also irregular and patchy stratification of endothelial or adventitial elements. Here and there perivascular spaces were markedly distended containing compound granular corpuscles.

In limited areas of the centrum semiovale, marked condensation of glia nuclei, mostly oligodendroglia, was prominent. In serial sections in the same areas, irregular amorphous granularlike material scattered freely in the interstitial tissue or incorporated in compound granular corpuscles was



ance of oligodendroglia. Note Nissl stain. Medium power magni-

evidenced (Fig. 8). In Nissl and hematoxylin and eosin preparations metachromatic bodies of different size, shape, and color intensity were seen scattered through the white matter, independently of the vascular pattern and ventricular system.

DISCUSSION

Neuropathologic findings in animals following experimental shock were discussed in detail in our previous paper(1). However, for a better evaluation of the present findings, a brief review of the literature will be helpful. From this review we gained the impression that some of the contradictory findings could be attributed to the following factors:

(1) *Potential or Intensity of the Electrical Current Used for the Induction of Convulsion.*—Some investigators have used the same convulsive dose currents in rats, guinea pigs, rabbits, cats, dogs, and monkeys irrespective of the weight and size of the animals.

(2) *Flow Duration of the Convulsive Dose Current.*—Some investigators have used only fractions of a second (0.1 or 0.2 second); others have prolonged the time to full seconds or several seconds and even minutes.

(3) *Size of Electrodes.*—Several investigators have used in small animals electrodes of such dimensions that would cover not only the prefrontal or precentral region of the frontal lobe (as in human subjects) but, at times, most of the cerebral structures.

(4) *Frequency of Induction of Convulsive Seizures.*—Some investigators have subjected their animals to 2 or 3 shocks weekly; others have applied it more frequently and in some instances even twice a day.

(5) *Total Number of Induced Convulsions.*—Some workers have studied the animals' brains following 1 or a few shocks; others have reported findings following 20, 30, and even 40 convulsions.

(6) *Selection of Experimental Animals.*—Different investigators have used various types of animals. It is known from different experimental sources that not all the experimental animals react in the same way to a given experimental investigation and that variable reactions occur in different species

and in animals of the same species as well. Echlin(4) found, for instance, that the pial blood vessels in cats contract vigorously under electric stimulation; dogs are less sensitive and monkeys less so than dogs. Besides, in experimental general pathology we must never forget that there is a chapter on comparative pathology yet to be written.

(7) *Nutritional Conditions of the Animals.*—Careful supervision of the animal diets and intake of food is very important for both control animals and those under experimentation. It is known that mild or subclinical vitamin B₁ or some of the B complex group, C, and, more seldom, K deficiencies may render more vulnerable or accelerate the appearance of some morphologic structural changes.

(8) *Possible Traumatic Complications.*—During experimentation some observers have obviated trauma to the head in the course or following the convulsive seizure; others may have neglected to protect the animals against such occurrence.

(9) *Quantitative Evaluation of the Mild Morphologic Alterations.*—The finding of an occasional acellular area or of a few nerve cells in a state of chromatolysis, or of a few metachromatic bodies or of a few hypertrophic glia cells, is not a sufficient criterion to attribute pathologic significance to the findings and establish causal connection with the electric shock. Normal animals may disclose occasionally the same changes. However, the quantitative difference between the same occurrence in the normal controls and the experimental animal is a factor which deserves evaluation. Finding in experimental material variations more frequently and more systematically than in the controls is, in our opinion, significant and the findings can justifiably be related to the experimental procedure. We therefore feel that the study of a few sections of only a few areas is inadequate and that serial studies of both control and experimental material is essential. On the basis of such studies we feel that the mild structural alterations, cellular and vascular, distributed particularly in those areas mostly subjected to the passage of the electrical current, are the effects of the experimental situation.

In the light of all the 9 variable elements above discussed, one might better understand

the same species as well, for instance, that the pial cats contract vigorously; dogs are less keys less so than dogs. Mental general pathology yet that there is a chapterology yet to be written.

Conditions of the Antisupervision of the animal—Food is very important in animals and those under it is known that mild or B₁ or some of the B and, more seldom, K render more vulnerable or variance of some morphologies.

Automatic Complications.—ation some observers have to the head in the course of convulsive seizure; others d to protect the animals rene.

Evaluation of the Mild ations.—The finding of ular area or of a few te of chromatolysis, or of atic bodies or of a few cells, is not a sufficient e pathologic significance l establish causal connec- ic shock. Normal animals ionally the same changes. itative difference between e in the normal controls ntal animal is a factor uation. Finding in ex- l variations more fre- systematically than in the opinion, significant and stifiably be related to the dure. We therefore feel a few sections of only a lequate and that serial ntrol and experimental l. On the basis of such the mild structural alter- vascular, distributed par- reas mostly subjected to e electrical current, are xperimental situation. l the 9 variable elements e might better understand

the histopathologic variations reported by the various investigators and running from insignificant or slight histologic changes (5-9) to severe neuropathologic findings (10-13). As to what may cause these changes in experimental electric shock, one may recall the data of the literature to the effect that different types of electric currents upon the central nervous tissue of mammals (14-17) revealed that a shocking electric current may affect nearly all the structure of the brain tissue, particularly the blood vessels (1, 4, 13, 15, 17-19). In our material, as already mentioned, the morphologic changes were distributed mostly in the regions subjected to the passage of the current and the blood vessels were found very often to react predominantly with vasomotor changes, mostly vasodilatation.

Spiegel and associates (20), studying the physicochemical effects of electrically induced convulsion in dogs, observed changes of the permeability of the vascular walls and increased permeability of the hemato-encephalic barrier. These findings are in accord with our observations of edema and distention of perivascular spaces, and presence of compound granular corpuscles.

The occurrence of petechial hemorrhages is not constant, even after numerous electric shocks, if the intensity and duration of the current are within low range. Their presence is only occasional in animals examined soon after the last shock. In animals which have been kept alive for long periods following the last shock, the occurrence of hemorrhages was inferred from the presence of various hematic pigments.

Regarding the character of the structural changes it seems to us that most of the neurocellular ones are of the reversible type and that a return to normal morphology and function in due time is very probable. However, here and there, particularly when higher potentials or longer duration flow or larger electrodes are used, the presence of glia proliferation, the individual cellular changes, the presence of compound granular corpuscles indicate that such structural alterations, no matter how slight, may ultimately become permanent. These changes, though small, circumscribed, and scattered, might, if increased in number, eventually influence mental processes and be responsible

for some of the organic types of reaction observed in a more or less transitory degree following electric shock therapy in human subjects.

In cases where morphologic damage is not detected it is conceivable that physicochemical changes may take place in the shocked brain structures, though not detectable with standard histologic techniques. In such instances, histometabolic studies of the nervous tissue may be helpful.

Our data refer naturally to convulsive seizures administered consecutively and not to series of 12 or more shocks followed by periods of rest between the series.

CONCLUSIONS

Five groups of *Maccacus rhesus* monkeys were subjected to 32-100 electrically induced convulsions with currents of 90 volts and duration of current flow of 0.3 sec. and 0.5 sec.; two different sized electrodes were used. The following findings were observed in animals sacrificed at varying intervals (from $\frac{1}{2}$ hour up to $1\frac{1}{2}$ years) following the last induced convulsion.

Functional and morphologic changes mostly related to the vascular system as indicated by increased permeability of the blood vessel walls (distension of the perivascular spaces surrounded at times by mild reactive glia proliferation, or compound granular corpuscles, and particularly diapedesis of blood elements).

The neuronal changes were mostly of the reversible type. When more intense and more frequently repeated current and longer duration of current were applied, occasional minute petechial hemorrhages resulted. This seems to support the contention that the degree of the lesions is somewhat proportional to the intensity of the electric current, the duration of the current flow and, to a lesser extent, the number of shocks.

The histologic alterations were more pronounced and more frequently observed in the areas traversed by the main path of the current.

In comparing some of the neuronal changes in experimental animals with the same occurrence in the control group, one must not only evaluate the qualitative changes but also the quantitative ones.

Differing somewhat from reports in human material, our conclusions are derived from the study of numerous blocks and at times of a whole hemisphere serially sectioned of experimental material, thus allowing detection of changes which may escape a more cursory investigation in human material.

Functional vasomotor changes may be at the base of the favorable therapeutic results reported in human cases. Reversible histometabolic and structural changes as well as permanent structural damage may be at the base of the more or less transitory mental symptoms of the organic reaction type which follow, at times, electroshock therapy.

BIBLIOGRAPHY

1. Ferraro, A., Roizin, L., and Helfand, M. Morphologic changes in the brain of monkeys following convulsions electrically induced. *J. Neuropath. & Exper. Neurol.*, 5: 285, 1946.
2. Wilcox, P. H. Electric shock therapy (A review of over 23,000 treatments using unidirectional currents). *Am. J. Psychiat.*, 104: 100, 1947.
3. Perlson, T. Psychologic studies on a patient who received 248 shock treatments. *Arch. Neurol. & Psychiat.*, 54: 409, 1945.
4. Echlin, F. A. Vasospasm and focal cerebral ischemia (An experimental study). *Arch. Neurol. & Psychiat.*, 47: 77, 1942.
5. Cerletti, U., and Bini, L. Le alterazioni istologiche del sistema nervoso nell' electroshock. *Riv. Sper. di Freniat.*, 64: 311, 1940.
6. Barrera, S. E., Lewis, N. D. C., Pacella, B., and Kalinowsky, L. Brain changes associated with electrically induced seizures. *Trans. Amer. Neurol. Assoc.*, June 1942, pg. 31.
7. Winkelman, N. W., and Moore, M. T. Neurohistologic findings in experimental electric shock treatment. *J. Neuropath. & Exper. Neurol.*, 3: 199, 1944.
8. Lidbeck, W. Pathologic changes in the brain after electric shock (An experimental study in dogs). *J. Neuropath. & Exper. Neurol.*, 3: 81, 1944.
9. Windle, W. F., Krieg, W. J. S., and Arieff, A. J. Failure to detect structural changes in the brain after electrical shock. *Quart. Bull.*, 19: 181, 1945.
10. Alpers, B. J., and Hughes, J. Changes in the brain after electrically induced convulsions in cats. *Arch. Neurol. & Psychiat.*, 47: 385, 1942.
11. Heilbrun, G., and Weil, A. Pathologic changes in the central nervous system in experimental electric shock. *Arch. Neurol. & Psychiat.*, 47: 918, 1942.
12. Neubürger, K. T., Whitehead, R. W., Rutledge, K., and Ebaugh, F. G. Pathologic changes in the brains of dogs given repeated electric shocks. *Am. J. Med. Sc.*, 204: 381, 1942.
13. Alexander, L., and Lowenbach, H. Experimental studies on electric shock treatment: The intracerebral vascular reaction as an indicator of the path of the current and threshold of early changes within the brain tissue. *J. Neuropath. & Exper. Neurol.*, 3: 139, 1944.
14. Jaffe, R. H. Electropathology. *Arch. Pathol.*, 5: 837, 1928.
15. MacMahon, H. E. Electric shock. *Am. J. Pathol.*, 5: 333, 1929.
16. Langworthy, O. R. Abnormalities produced in the central nervous system by electrical current. *J. Exper. Med.*, 51: 943, 1930.
17. Morrison, L. R., Weeks, A., and Cobb, S. Histopathology of different types of electric shock in mammalian brains. *J. Indust. Hyg.*, 12: 324, 1934.
18. Hyslop, G. H. Distant secondary circulatory and vasomotor reactions to accidental electric shock. *Bull. N.Y. Acad. Med.*, 21: 302, 1945.
19. Alexander, L., and Weeks, A. W. Electric shock; Importance of path, distribution and density of current in determining symptoms and pathology. *Am. J. Pathol.*, 17: 601, 1941.
20. Spiegel-Adolf, M., Speigel, E. A., Ashkenaz, E. W., and Lee, A. J. Physico-chemical effects of electrically induced convulsions. *J. Neuropath. & Exper. Neurol.*, 4: 277, 1945.